

CONTENTS *continued*

Adjunctive Benefits of Systemic Etoricoxib in Non-Surgical Treatment of Aggressive Periodontitis: Short-Term Evaluation 1719

Maria Cecília F. Azoubel, Viviane A. Sarmiento, Virna Cangussú, Eduardo Azoubel, Sandro Bittencourt, Fernando Q. Cunha, Ronaldo A. Ribeiro, Gerly Anne C. Brito

Etoricoxib, as an adjunct to non-surgical therapy, was not capable of producing additional clinical improvement when compared with conventional therapy alone; however, it produced an initial reduction in PGE₂ levels in the gingival fluid.

Risk Indicators for Increased Probing Depth in an Isolated Population in Brazil. 1726

Priscila Corraini, Vibeke Baelum, Cláudio Mendes Pannuti, Alessandro Nautili Pustiglioni, Giuseppe Alexandre Romito, Francisco Emílio Pustiglioni

Behavioral factors such as poor hygiene conditions and smoking played a significant role for increased probing depth in an isolated population of Brazil, and may be useful indicators of high-risk subjects for periodontal diseases.

Analysis of the Occlusal Stress Transmitted to the Inferior Alveolar Nerve by an Osseointegrated Threaded Fixture. 1735

G. Sammartino, G. Marenzi, R. Citarella, R. Ciccarelli, H-L Wang

Under variable bone density conditions, the pressures transferred to the alveolar nerve by a loaded threaded fixture are identified.

Estrogen Regulates Expression of Osteoprotegerin and RANKL in Human Periodontal Ligament Cells Through Estrogen Receptor Beta 1745

Li Liang, Ji-feng Yu, Yan Wang, Yin Ding

Estrogen may play an important role in exerting antiresorptive effects on alveolar bone, at least in part through the estrogen receptor, by increasing the expression level of osteoprotegerin versus that of RANKL in human periodontal ligament cells.

A Licorice Extract Reduces Lipopolysaccharide-Induced Proinflammatory Cytokine Secretion by Macrophages and Whole Blood. 1752

Charles Bodet, Vu Dang La, Stefan Gafner, Chantal Bergeron, Daniel Grenier

A licorice extract inhibited LPS-induced inflammatory response of immune cells and may possess interesting potential for the prevention and/or treatment of periodontitis.

Doxycycline Reduces Lipopolysaccharide-Induced Inflammatory Mediator Secretion in Macrophage and Ex Vivo Human Whole Blood Models 1762

Julia Cazalis, Charles Bodet, Guy Gagnon, Daniel Grenier

Doxycycline, through modulation of specific signaling pathways, can inhibit inflammatory mediator release by immune cells.



Alternative Anesthetic Technique for Maxillary Periodontal Surgery 1769

Dan Holtzclaw, Nicholas Toscano

The authors describe an alternate anesthesia approach for maxillary mucogingival surgery using an anterior middle superior alveolar injection; this technique has the potential to reduce undesirable side effects while limiting the total number of injections required for many maxillary periodontal surgeries.

DISCOVERY
SCIENCE

CASE SERIES AND
CASE REPORTS

Case Report

Alternative Anesthetic Technique for Maxillary Periodontal Surgery

Dan Holtzclaw* and Nicholas Toscano†

Background: Maxillary periodontal surgery typically requires multiple injections and may inadvertently affect facial structures such as the upper lip, lateral aspect of the nose, and lower eyelid. To minimize these sequelae and reduce the number of total injections, a relatively new injection technique has been proposed for maxillary procedures. The anterior middle superior alveolar (AMSA) injection is reported to effectively anesthetize maxillary teeth and associated gingival tissues extending from the buccal root of the first molar mesially to the central incisor with a single injection while avoiding undesirable side effects. The purpose of this article is to provide background information on the AMSA injection and demonstrate its use in a variety of maxillary periodontal surgeries.

Methods: Anesthesia was provided for five separate maxillary periodontal surgeries with unilateral or bilateral AMSA injections. Injections were administered via conventional syringe with a 27-gauge needle. Confirmation of anesthesia was subjectively tested with buccal mucosal sticks and palatal transgingival probing.

Results: The AMSA injection provided promising results for a variety of maxillary periodontal surgical procedures. Benefits of the AMSA injection included outstanding palatal hemostatic control, avoidance of undesirable collateral anesthesia, and a reduced number of cumulative injections. Drawbacks of the AMSA injection included occasionally inadequate buccal hemostatic control and short-lived anesthesia of the maxillary central incisors.

Conclusion: The AMSA injection is a novel anesthetic technique that may prove useful for certain maxillary periodontal surgeries. *J Periodontol* 2008; 79:1769-1772.

KEY WORDS

Case report; injection; local anesthesia; maxilla; palate.

Maxillary mucogingival surgery typically requires up to five injections to obtain anesthesia of the hard and soft tissues. Posterior superior alveolar, middle superior alveolar, and anterior superior alveolar block injections are used to anesthetize buccal tissues, whereas greater palatine and nasopalatine blocks are used for palatal anesthesia. Although this series of injections effectively anesthetizes maxillary tissues, it may also inadvertently affect facial structures, such as the upper lip, lateral aspect of the nose, and lower eyelid.^{1,2} To minimize these sequelae and reduce the number of total injections, a relatively new injection technique has been proposed for maxillary dental procedures.²⁻⁴ The anterior middle superior alveolar (AMSA) injection is reported to effectively anesthetize maxillary teeth and associated gingival tissues extending from the buccal root of the first molar mesially to the central incisor with a single injection (Fig. 1).³⁻⁵

In 1997, Friedman and Hochman⁶ defined the AMSA injection and a number of its clinical applications. The AMSA injection site is located on the hard palate at the intersection of a vertical line bisecting the premolars and a horizontal line halfway between the midpalatine raphe and the crest of the free gingival margin (Fig. 2).⁷ To avoid patient discomfort due to the tightly bound nature of the palatal tissue, the anesthetic agent should be injected into the site at a methodic rate of 0.5 ml per minute.³ Computer-controlled anesthetic delivery systems have been recommended to achieve this consistent anesthetic delivery rate, although this is not an absolute requirement.⁴ After slow deposition of the anesthetic agent, the bound nature of the palatal tissue promotes diffusion of the anesthetic agent through the palatal bone via numerous nutrient canals (Fig. 3).³ A successful AMSA injection typically blanches the palatal tissue in a unilateral fashion that does not cross the midline (Fig. 4).⁵ Following diffusion of the anesthetic agent, anesthesia of structures typically innervated by the greater palatine nerve, nasopalatine nerve, anterior superior alveolar nerve, and middle superior alveolar nerve is achieved.⁵⁻⁸

* Department of Periodontics, Naval Hospital Pensacola, U.S. Navy, Pensacola, FL.

† Department of Periodontics, National Naval Medical Center, U.S. Navy, Bethesda, MD.

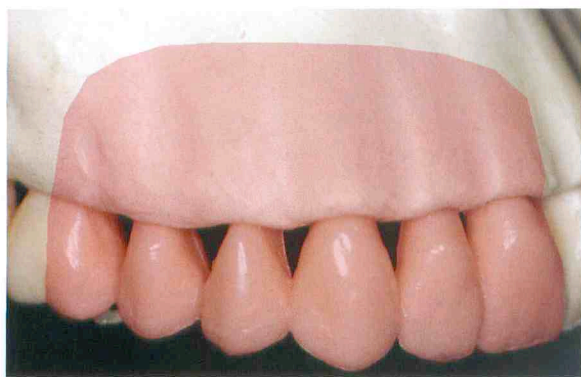

Figure 1.
Typical anesthetic range of AMSA injection.

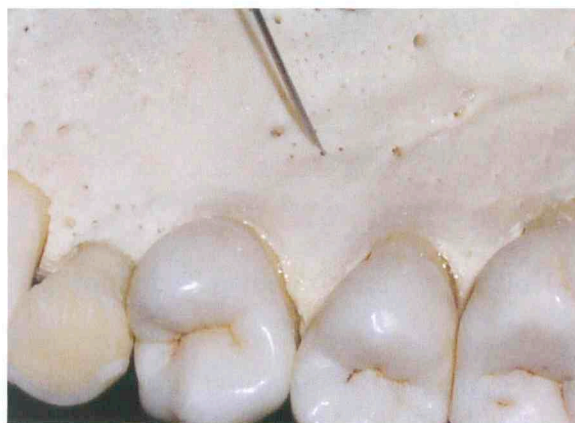

Figure 3.
Palatal nutrient canals.

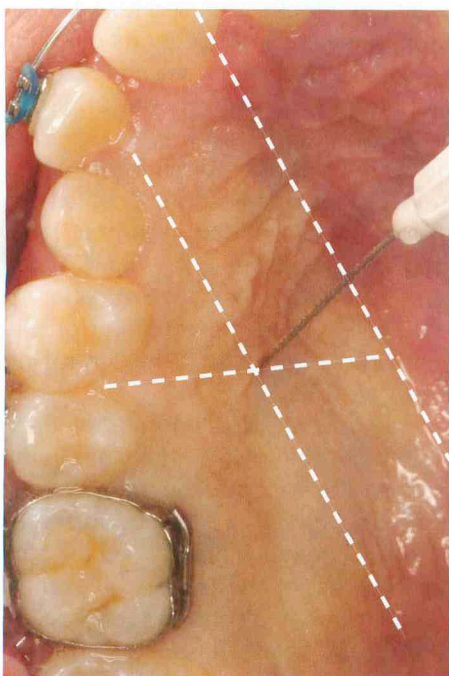


Figure 2.
Landmarks (dashed lines) for AMSA injection.

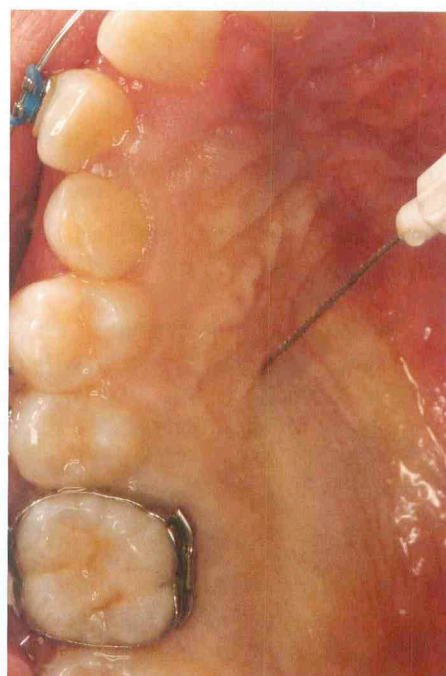


Figure 4.
Unilateral blanching of palatal tissue during AMSA injection.

Studies on the AMSA injection have demonstrated inconclusive evidence as to its effectiveness on pulpal tissue. Depending on the method of anesthetic delivery and tooth type, complete pulpal anesthesia from AMSA injections ranges from 20% to 86%.^{5,9} For soft tissue anesthesia, anecdotal reports on the AMSA injection have been positive, but controlled clinical studies are needed to corroborate these findings.

Although the AMSA injection has been recommended for procedures ranging from operative restorations to scaling and root planing, its effectiveness has not been evaluated for surgical procedures.^{3,4} This report de-

scribes five cases in which the AMSA injection was used for a variety of maxillary surgical procedures. All patients were treated at the Department of Periodontics, National Naval Medical Center, between September 2004 and June 2007.

CASE REPORTS

Case 1

A 48-year-old Asian male was referred for correction of Miller Class I recession defects in the maxillary right quadrant. After application of 20% benzocaine topical anesthetic, a conventional syringe with a 27-gauge

needle was used to deliver one carpule of 4% articaine with 1:100,000 epinephrine to the right palate via the AMSA injection over ~4 minutes. The patient reported no discomfort during the course of the injection. Anesthesia of the right palatal and buccal gingiva, confirmed by buccal mucosal sticks and palatal transgingival probing, was achieved within 5 minutes of the injection. Following root preparation with a 100-mg/ml tetracycline solution, a split-thickness tunneling incision with papilla preservation was created from the mesial aspect of tooth #4 to the distal aspect of tooth #7. A subepithelial connective tissue graft was harvested from the anesthetized palate using a trap-door approach and secured to the recipient site with bioabsorbable sutures. During the course of this procedure, the patient reported no discomfort and confirmed full sensation of his upper lip and nose. Additionally, the AMSA injection provided adequate palatal hemostatic control, and no subsequent anesthetic administration was required for the graft harvest. At post-surgical visits, healing of the recipient and donor sites was uneventful, and the patient reported no post-surgical discomfort or edema associated with the AMSA injection site.

Case 2

A 22-year-old African American male was diagnosed with a palatally impacted right maxillary canine and retained deciduous canine. Following 2 months of initial orthodontic therapy, the canine was exposed to secure a bracket/chain for extrusion. An AMSA injection to the right maxillary palate was performed in a similar fashion to case 1, and a full-thickness flap was extended palatally from the distal aspect of tooth #4 to the mesial aspect of tooth #8. After extraction of the deciduous canine and an additional supernumerary tooth, tooth #6 was exposed via selective osteoplasty. An orthodontic bracket/chain was bonded to tooth #6, and the periodontal flap was reapproximated with 4-0 silk sutures. The surgical procedure took ~90 minutes, and the patient reported no discomfort during the course of the surgery. At the 1-week follow-up visit, the patient reported no postoperative discomfort or swelling associated with the AMSA injection site.

Case 3

A 50-year-old white male was diagnosed with generalized severe chronic periodontitis and upon reevaluation was treatment planned for surgical therapy in the maxillary anterior sextant. Local anesthesia of the maxilla was obtained with bilateral AMSA injections administered in a similar fashion to case 1. After the onset of complete anesthesia, a full-thickness flap was reflected from teeth #5 to #12. Extensive palatal bone loss was noted with a vertical defect on the mesial aspect of tooth #9 and circumferential defects on teeth #7 and #8. After degranulation and root preparation with EDTA, demineralized freeze-dried bone allograft and enamel matrix

derivative were used to treat these severe defects. Toward the end of this procedure, the patient reported some discomfort associated with the central incisors, and facial infiltration anesthesia was administered for patient comfort. At the 1-week follow-up visit, the patient reported no postoperative discomfort or swelling at the sites of the AMSA injections.

Case 4

A 41-year-old African American female was diagnosed with generalized moderate chronic periodontitis that required surgical intervention in the maxillary right quadrant. An AMSA injection to the right maxillary palate was performed in a similar fashion to case 1. Following the onset of anesthesia, osseous surgery with an apically positioned flap was performed, and the patient reported no discomfort. Throughout the course of the procedure, the surgeon noted buccal hemorrhaging that partially obscured the surgical field. Judicious high-speed fluid evacuation was used to improve visibility. At the 1-week follow-up visit, the patient reported no postoperative discomfort or edema at the site of the AMSA injection.

Case 5

A 24-year-old African American male was referred for preprosthetic treatment of the maxillary anterior sextant. A planned, fixed partial denture required crown lengthening of teeth #8 and #10 with correction of a Siebert 1 ridge defect at the #9 edentulous site. Local anesthesia of the anterior maxilla was obtained with bilateral AMSA injections in a fashion similar to case 3. After the onset of complete anesthesia, a full-thickness flap was reflected from teeth #7 to #11. Teeth #8 and #10 were lengthened with a combination of ostectomy and soft tissue recontouring, whereas the ridge deficiency at site #9 was treated with a thick subepithelial connective tissue graft harvested from the palate. Throughout the procedure, the patient's smile line was continually evaluated to ensure proper gingival contours and esthetics. Although the AMSA provided adequate anesthesia and hemorrhage control to the palatal tissues, the patient complained of minor discomfort associated with the central incisors toward the end of the procedure. At post-surgical visits, healing of the recipient and donor sites was uneventful, and the patient reported no post-surgical discomfort or edema associated with the AMSA injection sites.

DISCUSSION

There are multiple ways to administer local anesthesia for dental procedures, and the type of injection given for a particular treatment usually is determined by the extent of the operative field. The ability of the AMSA injection to cover large maxillary surgical fields provides multiple benefits because it reduces the cumulative number of necessary injections. In addition to

improving patient comfort through the elimination of repetitive transmucosal punctures, the elimination of multiple injections reduces the total amount of delivered vasoconstrictor and may prove useful for cardiovascular-compromised patients requiring maxillary anesthesia. For maxillary anterior esthetic procedures, the AMSA's maintenance of upper lip function allows for continuous evaluation of gingival contours unimpeded by the "lip drooping" that typically occurs with traditional anesthetic techniques. With maxillary mucogingival procedures, the AMSA's palatal delivery of a full carpule of anesthetic with vasoconstrictor provides outstanding hemostasis and reduces the need for multiple reinjections to attain hemostatic control during graft harvest. Additionally, because the AMSA injection anesthetizes the buccal tissues from the palatal aspect, no vasoconstrictor affects the buccal gingiva, and outstanding blood supply is maintained for nourishment of the connective tissue graft.

Although the AMSA injection offers numerous benefits, it also has disadvantages that must be considered. In many articles,³⁻⁸ the use of a computer-assisted injection system is recommended as the best method for administering AMSA injections. The added cost of this anesthetic delivery system is one potential drawback of the AMSA injection. A second disadvantage is its long administration time. Some patients may find it disconcerting to have an injection last 4 minutes, and attempts to speed up the AMSA injection may lead to increased patient discomfort at the injection site. One reported benefit of the AMSA injection, the reduction of cumulative anesthetic vasoconstrictor, may also prove to be problematic for certain surgical procedures. Although the reduction in vasoconstrictor proves beneficial for cardiovascular-compromised patients, it may lead to less than desirable hemostatic control. Because the AMSA eliminates the need for multiple injections, less vasoconstrictor enters the buccal tissues, and a subsequent decline in hemostasis may obscure portions of the surgical field. Finally, in this series of case reports, a trend of short-lived anesthesia in the maxillary central incisor region was anecdotally noted.

CONCLUSIONS

This series of case reports describes the technique and various applications for the AMSA injection in

periodontal surgical procedures. Although it is in no way intended to replace traditional dental anesthetic methods, the AMSA injection may prove useful in certain situations and adds to the clinician's repertoire of anesthetic techniques.

ACKNOWLEDGMENTS

This article does not represent the views of the United States Navy, the National Naval Medical Center, or Naval Hospital Pensacola. The authors report no conflicts of interest related to this article.

REFERENCES

1. Malamed SF. *Handbook of Local Anesthesia*, 5th ed. St. Louis: Mosby; 2004:213-216.
2. Gomolka KA. The AMSA block: Local anesthesia without collateral numbness. *CDS Rev* 2000;93:34.
3. Friedman MJ, Hochman MN. Using AMSA and P-ASA nerve blocks for esthetic restorative dentistry. *Gen Dent* 2001;49:506-511.
4. Loomer PM, Perry DA. Computer-controlled delivery versus syringe delivery of local anesthetic injections for therapeutic scaling and root planing. *J Am Dent Assoc* 2004;135:358-365.
5. Lee S, Reader A, Nusstein J, Beck M, Weaver J. Anesthetic efficacy of the anterior middle superior alveolar (AMSA) injection. *Anesth Prog* 2004;51:80-89.
6. Friedman MJ, Hochman MN. A 21st century computerized injection system for local pain control. *Compend Contin Educ Dent* 1997;18:995-1003.
7. Perry DA, Loomer PM. Maximizing pain control: The AMSA injection can provide anesthesia with fewer injections and less pain. *Dimens Dent Hyg* 2003;1:28-33.
8. Nusstein J, Lee S, Reader A, Beck M, Weaver J. Injection pain and postinjection pain of the anterior middle superior alveolar injection administered with the Wand or conventional syringe. *Oral Surg Oral Med Oral Pathol Oral Radiol Endod* 2004;98:124-131.
9. Fukayama H, Yoshikawa F, Kohase H, Umino M, Suzaki N. Efficacy of anterior and middle superior alveolar (AMSA) anesthesia using a new injection system: The Wand. *Quintessence Int* 2003;34:537-541.

Correspondence: Dr. Dan Holtzclaw, Naval Branch Health Clinic, Naval Air Station Pensacola, 450 Turner St., Pensacola, FL 32508.

Submitted December 3, 2007; accepted for publication January 8, 2008.